

CLINICAL UPDATE

Adult Vulval Lichen Sclerosus

Authors:

Dr Lisa Roche, Dr Cliona Murphy, Dr Ciara McCarthy, Dr Eilis NicDhonncha, Dr Claire Brennan, Prof Aoife Lally, Prof Noirin Russell, Prof Michelle Murphy

February 2025

Adult Vulval Lichen Sclerosus

Introduction

Lichen sclerosus (LS) is a relatively common chronic inflammatory skin condition; in affected women and female children, it typically affects the ano-genital region but can affect other extragenital sites. It was first described in 1881 and has been referred to by various names, however, the term lichen sclerosus was adopted by the ISSVD (the International Society for the Study of Vulvovaginal Disease) in 1976 (Chamli & Souissi, 2023). The true prevalence of LS is unknown due to under-diagnosis, but estimates suggest that it affects between 1 in 1000 and 1 in 300 in the general population (Kreuter, et al., 2013); similarly, female to male ratios are variously estimated to be 1:1 to 10:1, but it is generally accepted to be more common in females; mean age at diagnosis in adult women is 52-60 years (Kreuter, et al., 2013).

Although LS is generally considered to be an autoimmune condition, the exact aetiology remains unclear, but is likely multifactorial (Chamli & Souissi, 2023). Histological findings are characterised by band-like lymphocytic infiltrate, dermal oedema and orthokeratotic hyperkeratosis; other changes are typically determined by the disease duration (Fistarol & Itin, 2013). While LS is not itself a pre-malignant condition, it is associated with an increased risk of vulval cancer; this is via the development of vulval intraepithelial neoplasia, differentiated type, within LS affected skin (Pérez-López & Vieira-Baptista, 2017), the estimated risk of development of vulval cancer is up to 5% (Halonen, et al., 2017).

Clinical features

Symptoms include:

- Itch (primary symptom)
- Soreness/ burning pain (consequence of erosion or fissures)
- Dysuria
- Superficial dyspareunia
- May be (rarely) asymptomatic

Itch is the primary symptom of LS, occurring in 93% of cases (Lee & Fischer, Diagnosis and Treatment of Vulvar Lichen Sclerosus: An Update for Dermatologists, 2018); it is often intense, and can impact upon sleep or activities of daily living. Pain typically arises as a result of erosion and fissuring (Fischer G. O., 1996). Tissue fusion in a midline distribution may lead to issues with micturition and resultant dysuria. All of these factors contribute to discomfort during sexual intercourse, which is common in LS. In 9% of cases, LS is asymptomatic (Tasker & Wojnarowska, 2003), and incidentally noted on examination of the genital skin for another reason.

Signs of LS (Figure1):

- Sclerotic change ‘white papules and plaques’
- Ecchymosis
- Fissuring
- Adhesion or ‘agglutination’ (typically of the labia minora, of the midline with sealing of the clitoral hood, and of the vaginal introitus with narrowing and rarely obliteration)
- Loss of vulval architecture (‘plastic doll’ appearance)
- ‘Figure of 8’ involvement (involvement of the perineal and perianal skin, can extend to the buttocks or genito-crural folds)
- The vagina and cervix are **not** involved

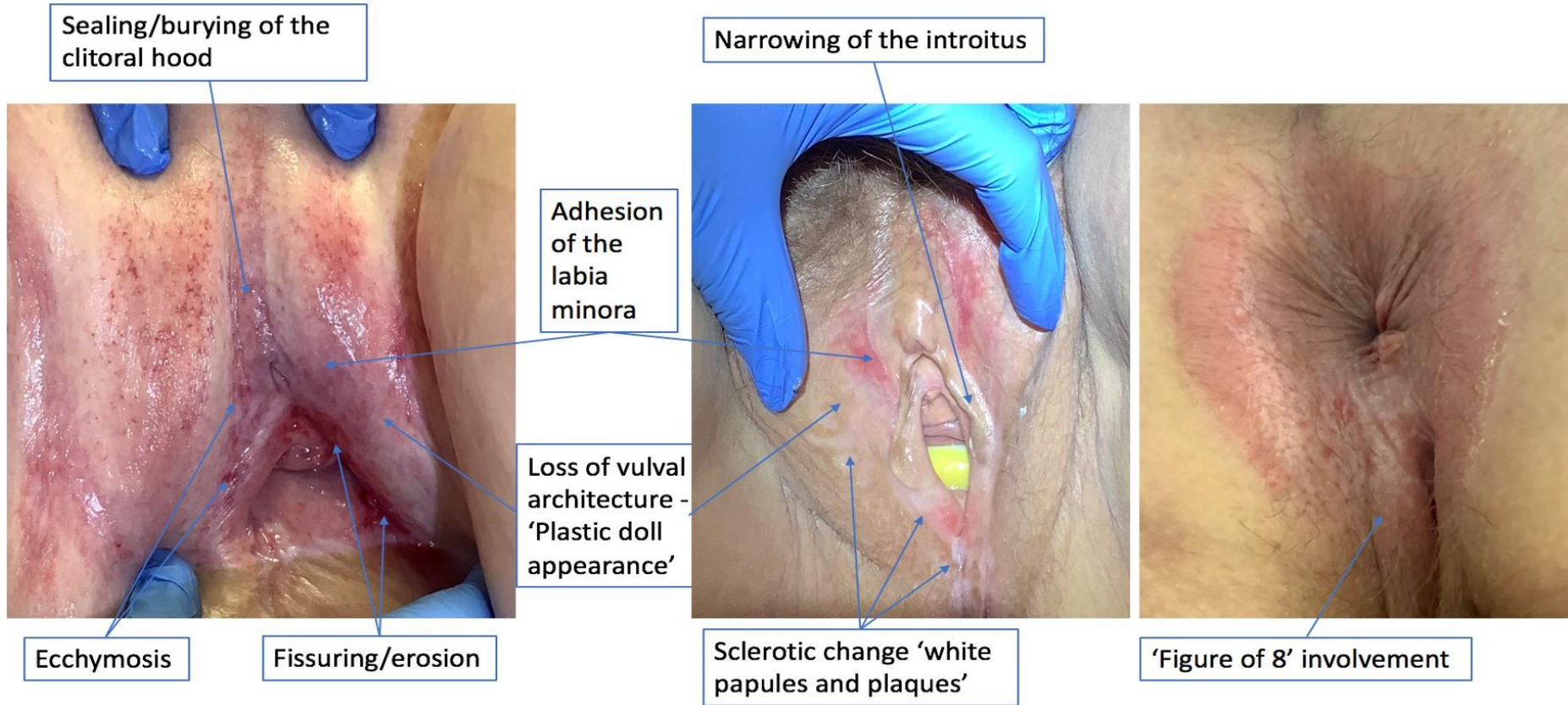
Early LS may manifest as non-specific erythema; however skin fragility of involved tissues is a hallmark sign of LS, resulting in erosion, fissuring, the development of purpura and ecchymosis, with tissue tearing during sexual intercourse or clinical examination occurring commonly (Fistarol & Itin, 2013). The involved tissues become pale and sclerotic and later, atrophic resulting in the classic ‘crinkled’ or ‘cigarette-paper’ appearance; the resultant scarring leads to architectural distortion of the typical structures, classically with resorption, and eventually complete loss of, the labia minora and clitoral burying. Narrowing of the introitus may occur in severe cases (Fistarol & Itin, 2013).

Signs of early disease	erythema, particularly at the periclitoral hood, white papules and plaques.
Signs of ‘active’ disease	ecchymosis fissuring and superficial erosion.
Established signs of LS	sclerotic changes including advanced white papules and plaques, midline adhesion/agglutination, loss of vulval architecture.

Key practice point

The hallmark feature of LS is loss of architecture.

Figure 1: Signs of LS



Hypertrophic LS

Non-sclerotic LS is a subtype of LS where dermal sclerosis is absent histologically, sometimes described as ‘lichen sclerosus sine sclerosis’ (Weyers, 2015); involved tissues may appear clinically atypical, as thickened, whitish plaques with accentuated skin folds, with appearances more in keeping with lichen simplex chronicus or a psoriasiform eruption. (Day, Selim, Allbritton, Scurry, & ISSVD Difficult Pathologic Diagnoses Committee, 2023) (Hagedorn, Golüke, & Mall, 2003) (Weyers, Hypertrophic lichen sclerosus with dyskeratosis and parakeratosis--a common presentation of vulvar lichen sclerosus not associated with a significant risk of malignancy., 2013). Histopathological findings lack the classical subepidermal zone of sclerosis, and instead, dyskeratosis and parakeratosis are common (Weyers, 2015). Therefore, hypertrophic LS may provide a diagnostic challenge as neither clinical nor histopathological findings are typical.

Although the histological findings in non-sclerotic lichen sclerosus have been determined to fall into one of four subgroups (Day, Selim, Allbritton, Scurry, & ISSVD Difficult Pathologic Diagnoses Committee, 2023), insufficient evidence exists to correlate these with neoplastic risk. Those found to have clinical findings suspicious for hypertrophic LS should be referred to secondary care for evaluation in light of potential diagnostic challenges and unclear prognosis.

Key practice point

Patients found to have clinical findings suspicious for hypertrophic LS should be referred to secondary care for evaluation in light of the potential diagnostic challenge and unclear prognosis.

Clinical diagnosis

LS is primarily a clinical diagnosis; confirmatory biopsy is not required if the clinical findings are typical (McCarthy, et al., 2019).

Biopsy may be recommended (within a secondary care setting) if there is diagnostic uncertainty, atypical clinical findings, or if there is a lack of expected response to adequate treatment. However, the benefit of a biopsy must be weighed against the discomfort experienced by the patient, cost, and the risk of a false negative result potentially eliminating LS from the differential diagnoses.

Biopsy must be considered if there is any suspicion of neoplastic change e.g. in non-healing or clinically suspicious areas, or in areas non-responsive to adequate treatment.

Biopsy should be taken from the most active appearing area of involved tissue (Lewis, et al., 2018).

Differential diagnosis:

- Lichen planus
- Lichen simplex chronicus
- Immunobullous disorders e.g. mucous membrane pemphigoid
- Plasma cell vulvitis
- Vulval intraepithelial neoplasia (VIN)
- Squamous cell carcinoma (SCC)
- Warts
- Psoriasis

Other conditions such as superimposed infections e.g. candida, or contact dermatitis, may coexist and should be treated.

Key Practice Point

LS is a clinical diagnosis. Confirmatory biopsy is not required routinely.

Key Practice Point

Biopsy must be considered if there is any suspicion of neoplastic change or if no response despite adequate dose and frequency of steroid.

Location of care

It is reasonable to commence treatment in primary care with an informed clinical impression of LS based on typical findings. If awaiting a referral appointment, standard treatment may be commenced and continued while awaiting review.

Stable, uncomplicated and symptomatically well controlled LS may be managed safely in primary care.

The patient should be encouraged to have a yearly vulval exam and to seek medical advice regarding any findings or new symptoms of concern.

Patients should be counselled to seek review if they identify any areas of concern (“lumps”, “bumps”, “non-healing areas”) that do not respond to a trial of 6 weeks of treatment with a potent topical corticosteroid, or, if they experience loss of control of previously stable disease without any change in treatment regime.

Certain clinical scenarios should prompt urgent referral to a specialised service, if the patient is not already in attendance:

- Lack of clinical response with adequate standard treatment
- Evidence of a well demarcated plaque not responding to standard treatment
- Any areas suspicious for neoplasia or established signs of cancer
- Concurrent VIN (vulval intraepithelial neoplasia) and LS
- Diagnostic doubt
- Significant loss of architecture or loss of function
- Any suspicion of hypertrophic LS (clinical photos)

Patients who develop vulval SCC with background changes of LS noted on histology need referral to an appropriate specialist for active management of LS.

Referral to secondary care should be based on specialist expertise in managing complex cases of LS, regardless of speciality (dermatology, gynaecology, genitourinary medicine).

Screening

Autoimmune diseases (especially thyroid disease) are frequently associated with LS in females, however studies do not confirm these associations (Higgins & Cruickshank, 2012).

- Screening for hypothyroidism should be based on clinical picture, family and personal history.
- Wider screening for autoimmunity should be based on clinical discretion if features of autoimmune disease are present.
- There is no role for routine ANA testing.

Treatment; general considerations, initiation, maintenance

General considerations

- Document clearly the clinical findings at baseline (preferably via patient held photograph, alternatively via clinical photograph, and/or clinical diagram).
- Provide clear application guidelines for the prescribed topical regime, preferably with accompanying written instruction.
- Ensure affected areas are actually treated – patient should be well informed and have clarity on site of application, ideally by clearly identifying the areas to be treated to the patient using a mirror if required.

- Advise patients to undertake regular self-examination and educate them regarding the red flag symptoms for development of neoplastic change that should prompt expedited clinical review.
- Proactively address potential barriers to treatment which are significant amongst patients with LS (Nic Dhonncha, et al., 2021); particularly patient fear of treatment with potent topical corticosteroids in the genital area, and the perceived associated risks; mixed messaging from other health care professionals (Nic Dhonncha & Murphy, 2022); and confusion regarding correct site of application.

Greater awareness of the both the signs and symptoms of LS, and knowledge of typical treatment regimes, amongst healthcare professionals within primary care, midwifery/obstetric care and pharmacy, has the potential to improve the experiences of patients with LS. The opportunity provided by patient interactions with these health care professionals for timely recognition of signs and symptoms may facilitate earlier diagnosis, and knowledge of the typical topical regimens may reduce patients receiving mixed messaging regarding the safety profile of use of potent topical corticosteroids in the genital region.

There is some evidence supporting the clinical benefit emollient regimes in maintenance of LS, and they may provide symptomatic relief after initial treatment with topical corticosteroids (Simonart, Lahaye, & Simonart, 2008) (Cattaneo, et al., 1996).

Topical corticosteroid regimens

It should be noted that most patients will respond symptomatically and histologically to treatment with topical corticosteroids (TCS) of adequate potency and duration; if they do not, the diagnosis should be reappraised with consideration for other factors (see treatment failure section below) (Fistarol & Itin, 2013). ‘Steroid-phobia’ should be actively addressed.

Although robust, long-term studies on the safety and efficacy of potent topical corticosteroids are lacking in vulval LS (Pergialiotis, et al., 2020), several studies report on improvements in both symptoms and skin changes with ultrapotent topical steroids (Cooper, Gao, Powell, & Wojnarowska, 2004); a large prospective single-centre longitudinal cohort study of 507 women with follow up ranging to 6.8 years (Lee, Bradford, & Fischer, 2015), describes individualised topical corticosteroid regimens achieving significant modifying effects on the course of LS in symptom control, scarring and vulval carcinoma incidence and notable differences between compliant and partially compliant groups, with minimal adverse events noted. A retrospective study of 129 patients with a mean duration of follow up of 6.2 years concludes that long term treatment of adult vulval LS with moderate potency TCS is safe and effective (Bradford & Fischer, 2010). Several recent reviews conclude that potent topical corticosteroid based treatment regimens are the gold standard in vulval LS; (De Luca,

et al., 2023) (Borghi & Corazza, Novel Therapeutic Approaches and Targets for Treatment of Vulvar Lichen Sclerosus., 2021) (Funaro, 2004).

The ideal potency of the topical corticosteroid used in the management of vulval lichen sclerosus from an efficacy and safety perspective is also debated; several studies explore mometasone furoate as an alternative to clobetasol propionate; a randomised controlled trial (RCT) of 54 patients over 12 weeks concluded that clobetasol propionate and mometasone furoate are similarly efficacious and well tolerated and are recommended as first line treatment options (Virgili, Borghi, Toni, Minghetti, & Corazza, 2014), these findings were further confirmed when 48 patients were followed to 52 weeks with no difference noted between the two steroids groups (Corazza, Borghi, Minghetti, Toni, & Virgili, 2016); Murina et al conclude similarly with a comparative study of 96 women with 12 month follow up (Murina, et al., 2015). Several other studies investigated mometasone furoate (Virgili, Borghi, Minghetti, & Corazza, 2014) with a 2015 review concluding that mometasone furoate shows similar efficacy and safety to clobetasol propionate (Virgili, Corazza, Minghetti, & Borghi, 2015).

Topical corticosteroid regimens within published studies demonstrate significant heterogeneity (Lewis, 2015) (Pergialiotis, et al., 2020). A 2021 scoping review concludes that high potency topical corticosteroids are the standard of care and should be the first line management consideration; follow up should be 3-6 monthly for 2 years and then at least yearly (to ensure treatment adequacy and compliance) and that follow up should occur in specialised clinics particularly with persisting symptoms, thickened skin and a history of neoplastic lesions (Singh, Mishra, & Ghatage, 2021) Borghi et al conclude similarly (Borghi & Corazza, 2021), however there is no evidence to support any particular surveillance regime; follow up should be tailored to individual disease.

Proactive maintenance therapy – twice weekly application of mometasone furoate 0.1% ointment after active treatment - was explored in a small RCT of 27 patients over 56 weeks as found to be effective in maintaining remission (Virgili, Minghetti, Borghi, & Corazza, 2013). A 2015 RCT found that both tapering and continuous application of potent topical steroid, in this case, with mometasone furoate 0.1% demonstrated similar efficacy without differences in patient adherence with regimes (Borghi, Corazza, Minghetti, Toni, & Virgili, 2015).

Treatment; Initial treatment regime

Treat active areas ‘copiously’.

Potent or ultra-potent topical corticosteroids should be prescribed e.g. Dermovate (clobetasol 0.05%)

Ointment formulation is preferable to a cream formulation (Corazza, Virgili, Toni, & Borghi, 2018).

Exact regimes can be tailored to disease severity; a typical regime could include: clobetasol 0.05% ointment applied generously daily x12 weeks and review.

Treatment; Maintenance treatment

Specific regimes should be individualised for each patient but include topical corticosteroid on a regular basis in a preventative capacity. A typical regime may be clobetasol 0.05% once/twice weekly to maintain control of disease activity.

Maintenance treatment should aim to (Yeon, et al., 2021):

- Maintain normal/near normal colour/texture of vulval skin (pre-existing architectural distortion will not change despite ongoing adequate treatment)
- Control symptoms
- Prevent future scarring
- Minimise side effects
- Reduce carcinoma risk

When weaning treatment, decrease frequency of application rather than volume used.

Key practice point

Topical steroid is the first line treatment for Lichen Sclerosus. Nonresponse should prompt reappraisal of the diagnosis.

Treatment failure

The primary reason for treatment failure in LS is non-compliance with topical corticosteroid regimes for a variety of reasons.

It should be noted that certain patients within vulnerable populations may struggle to achieve adequate compliance with topical treatment or maintenance regimes; e.g. those with psychiatric diagnoses, those with certain physical disabilities. These patients are likely to require additional support to achieve both control of active disease, and adequate disease maintenance.

For patients who have failed to respond to treatment at initial 3 monthly review, review adequacy of treatment, ensuring; generous application, right site, correct frequency; if these issues have been addressed, and treatment response remains inadequate, referral onward to secondary care is recommended. Keep these patients under 3-6 monthly follow up until the disease responds and clinical findings remain stable or, a

definitive diagnosis is confirmed; consider biopsy if not already performed or consider neoplastic change and biopsy to rule out this, as required

Signs of active uncontrolled disease include erosion, ecchymoses and fissuring; scarring and architectural distortion are not reversible once established.

If symptoms/signs atypical consider:

- superimposed infection e.g. candidiasis,
- allergic contact dermatitis
- local topical corticosteroid side effects
- vulvodynia
- malignant transformation

If concerns regarding symptoms/signs of adverse side effects of TCS, adjust regime accordingly.

Preferably, severe disease should be managed in a specialised clinic within secondary care; these would ideally include specialised nurses with expertise in vulval disease and access to multidisciplinary team discussion incorporating the experience of fields including dermatology, gynaecology, gynae-oncology and histopathology would be available.

New and emerging treatments

Vulval skin conditions are best managed by an experienced multi-disciplinary team which includes dermatologists, gynaecologists and pathologists.

Most patients with LS – 96% in one study - respond well to adequate treatment with potent topical corticosteroids (Cooper, Gao, Powell, & Wojnarowska, 2004). It is important that patients are reassured and counselled regarding the effectiveness of this approach and informed of this prior to interactions with other allied healthcare professionals e.g. pharmacists (Nic Dhonncha & Murphy, Attitudes and advice-giving behaviours of pharmacists in relation to topical corticosteroid use for patients with lichen sclerosus., 2022).

Patients with chronic diseases like LS can be susceptible to claims regarding novel therapies. Clinicians have a duty of care to provide evidence-based information and inform patients of the benefits and limitations of available treatments.

1. Topical sex hormones

The use of topical sex hormones cannot be recommended in the management of LS (Chi, et al., 2011).

Topical oestrogens

There is insufficient evidence to support the use of topical oestrogens in LS. Post-menopausal vaginal atrophy may co-exist with LS, topical oestrogens are a recognised treatment for this condition but there is insufficient evidence to support the use of topical oestrogens in LS alone.

Topical testosterone

Several randomised controlled trials have found no significant benefit for topical testosterone or dihydrotestosterone compared to clobetasol propionate 0.05% (Bracco, et al., Clinical and histologic effects of topical treatments of vulval lichen sclerosus. A critical evaluation., 1993) (Cattaneo, et al., 1992) (Paslin, 1996) (Paslin, Treatment of lichen sclerosus with topical dihydrotestosterone., 1991) (Sideri, Origoni, Spinaci, & Ferrari, 1994). Another trial found that topical testosterone worsened symptoms when used in maintenance phase of treatment (Cattaneo, et al., Testosterone maintenance therapy. Effects on vulvar lichen sclerosus treated with clobetasol propionate., 1996). (Cattaneo, et al., 1996)

Topical progesterone

A small RCT investigating progesterone 2% versus clobetasol propionate and a small RCT comparing progesterone 8% versus clobetasol propionate suggest topical progesterone is not superior to topical clobetasol propionate (Bracco, Carli, & Sonni, 1993) (Günthert, et al., 2022); one small RCT suggested topical progesterone may be effective in LS by inducing epidermal growth factor release or by influencing factors that interfere with its action (Leone, Gerbaldo, Caldana, Leone, & Capitano, 1993).

Key practice point

Topical sex hormones are not recommended in the management of adult female genital lichen sclerosus.

2. Topical calcineurin inhibitors

Use of topical calcineurin inhibitors (TCI) remains somewhat controversial in adult female LS; some authors propose that they are safe and effective and even advantageous over potent topical corticosteroids due to the lack of associated risk of local atrophy, however this is typically attributed to the assumption that potent topical corticosteroids contribute to atrophy in genital LS in the first place, which is not well established, as it is more likely related to the disease process itself (Fistarol & Itin, 2013). Other authors remain wary of their use in genital LS due to the associated malignant potential of the disease, fearful that TCI may theoretically increase this risk (Fischer & Bradford, 2007). Additionally, the cost of TCIs far exceeds that of potent topical corticosteroids, this may be especially relevant in the management of chronic conditions such as LS which require life-long management (Fistarol & Itin, 2013). A 2009 review suggests that although there is evidence for their efficacy and tolerability,

clinicians should exercise caution with the use of TCIs in genital LS because of this uncertainty surrounding the potential for malignant potential (Yesudian, 2009).

Pimecrolimus

A small prospective trial of pimecrolimus 1% cream in vulval LS in 16 post-menopausal women demonstrated significant improvement in symptoms and clinical appearance with 10 patients demonstrating complete remission at 12 month follow up (Oskay, Sezer, Genç, & Kutluay, 2007). An RCT investigating pimecrolimus versus clobetasol (Goldstein, Creasey, Pfau, Phillips, & Burrows, 2011) found that although both agents were effective, clobetasol remained superior to pimecrolimus with no adverse events; however the follow up period was short at 12 weeks; author recommendation was for clobetasol to remain first line.

Tacrolimus

Two small pilot studies of use of tacrolimus in women with vulval LS (Luesley, & Downey, 2006) (Virgili, Lauriola, Mantovani, & Corazza, 2007) report a rate of complete remission varying from 12.5% - 36% and a larger phase II multicentre trial (Hengge, et al., 2006) of 49 women (as well as 32 men and 3 girls) investigated topical tacrolimus 0.1% with an 18-month follow up; complete remission was found in 43% and partial remission in 34%, and no malignancy was noted during the follow up period. A study of 10 post-menopausal women with recalcitrant LS treated with twice daily tacrolimus 0.1% for 8 weeks (Sotiriou, Apalla, Patsatsi, & Panagiotidou, 2009); improvements were noticed in symptoms but there were minimal changes noted in clinical findings of hyperkeratosis, atrophy, sclerosis and depigmentation. A 2014 RCT of 55 patients prospectively evaluating clobetasol propionate 0.05% versus topical tacrolimus 0.1% in vulval LS (Funaro, Lovett, Leroux, & Powell, 2014) found that topical clobetasol was significantly more effective in treating vulval LS than topical tacrolimus.

A 2011 Cochrane database systematic review (Chi, et al., 2011) found that pimecrolimus was less effective than clobetasol in improving appearance or reducing inflammation; Australian LS management guidelines conclude that topical calcineurin inhibitors do not offer any advantage over topical corticosteroids (Yeon, et al., 2021).

Key practice point

The use of topical calcineurin inhibitors is not recommended as first-line treatment in adult vulval lichen sclerosus as they do not offer any advantage over use of topical corticosteroids, and their potential for harm has not been clearly ruled out.

3. Stem Cell therapies and Platelet rich plasma

Stem cell therapies and platelet rich plasma (PRP) therapy do not currently have sufficient evidence to merit recommendation (Eshtiaghi & Sadownik, 2019). One group, Casabona et al (Casabona, Robello, & Cogliandro, Nuova terapia degli esiti di

lichen sclerosis della vulva con L'impiego de cellule multipotenti di derivazione adipose e plasma ricco di piastrine: case report., 2008) (Casabona, Priano, & Vallerino, 2010) report promising results using both stem cell therapy and platelet rich plasma, however it is unclear whether both components are required to achieve results. Both a 2021 review and more recent review of available evidence (Villalpando, Wyles, Schaefer, Bodiford, & Bruce, 2021) (Paganelli, et al., 2023) conclude that although these modalities, especially in combination with standard therapy, may show some promise, available evidence is currently insufficient, heterogenous and lacks long term follow up data.

It must also be borne in mind, that although autologous PRP utilises the patient's own blood products, homologous PRP potentially exposes the patient to blood borne infection as with other blood products. Additionally, individual provider cost is highly variable and may be significant, despite lack of consensus on protocol or established efficacy.

Key practice point

Current evidence is not sufficient to recommend stem cell therapies/PRP treatment in adult female genital lichen sclerosis and there exists potential for harm.

4. LASER treatment

One systematic review (Tasker, Kirby, Grindlay, Lewis, & Simpson, 2021) from 2021 exploring the evidence for use of LASER therapy in genital lichen sclerosis concluded that available evidence was insufficient to support its use; results were heterogenous and the methodological quality of available studies was low. A more recent review concluded similarly (Gil-Villalba, Ayen-Rodriguez, Naranjo-Diaz, & Ruiz-Villaverde, 2023). An RCT of 40 women treated with CO₂ LASER or sham LASER showed no significant histopathological difference between groups after 8 weeks (Mitchell, et al., 2021). Two small RCTs compared LASER therapy with topical corticosteroid for LS (Burkett, et al., 2021) (Bizjak Ogrinc, Senčar, Luzar, & Lukanović, 2019) with 90 woman in total across both studies; although results favoured the LASER group, follow up did not exceed 6 months in any of these studies. A more recent RCT compared normal and low dose CO₂ LASER ablation in 67 patient with LS with no benefit at higher doses, with follow up to 18 weeks only (Krause, et al., 2023).

Key practice point

Current evidence is not sufficient to recommend LASER treatment in adult female genital lichen sclerosis, and there exists potential for harm.

5. Surgery

In adult female patients with LS, there is insufficient evidence for surgical approaches outside of management of vulval intraepithelial neoplasia or malignancy. In rare cases surgery may be used as a strategy to correct scarring that has resulted in functional impairment but should be combined with standard treatment with topical corticosteroids. There is no place for surgery in the management of uncomplicated LS in adult women (Funaro, Lichen sclerosus: a review and practical approach., 2004).

Key practice point

Surgical treatment in uncomplicated adult female genital lichen sclerosus is not recommended.

Psychological Impact

Lichen sclerosus is widely acknowledged to cause a significant detrimental impact on the quality of life of those affected, with a large proportion of women suffering with sexual dysfunction, which may persist even after successful treatment. (Pope, et al., 2022)

There are several factors which can cause this psychosexual distress, including unhappiness with the appearance of genitalia, vulval pain caused by the presence of active disease, as well as reduced sexual function due to changes in the vulvar architecture. (Haefner, et al., 2014) These factors can result in negative body image, as well as dyspareunia, decreased orgasm and anorgasmia. (Yıldız, et al., 2022) Due to the sensitive nature and location of LS, women suffering with the condition may be reluctant to disclose symptoms and present at a later stage. Early recognition of the condition in women presenting with vulval symptoms accompanied by prompt physical assessment and initiation of appropriate treatment, may help to improve symptom control, prevent architectural changes and lead to better quality of life outcomes.

An open discussion on the impact the condition is having on the woman's sexual health should be carried out at the time of presentation as well as on subsequent review appointments, with referral for further counselling/psychological support if needed, depending on availability of supports locally. (Vittrup, et al., 2022)

Follow up

Patients should be seen 3/12 after initial diagnosis and treatment trial to assess their response. Once control has been achieved, patients should be advised to continue the topical maintenance regime. Patients should decrease the frequency of application of the potent topical steroid, rather than volume used. In the authors

experience, this is likely to both maintain symptom control, and decrease the risk of development of skin cancer.

The patient should be encouraged to have a yearly vulval exam and to seek medical advice regarding any findings or new symptoms of concern. Stable uncomplicated disease which is well controlled may be safely managed by a primary care physician.

Key Practice Point

Annual vulval exam is recommended. This may be in primary care in well controlled, uncomplicated LS cases.

Conclusion

Vulval LS is not uncommon amongst adult women, and moreover, its prevalence is likely underestimated. The disease has the potential to be associated with significant impacts upon quality of life and sexual functioning (Van de Nieuwenhof, et al., 2010) particularly, if left untreated or poorly managed; additionally, it is associated with a small but significant lifetime risk of the development of skin cancer. Early diagnosis and treatment is known to have a positive impact on the disease progression (Cooper, Gao, Powell, & Wojnarowska, 2004).

This clinical update document aims:

- **to facilitate early diagnosis and treatment of LS for affected patients**
 - **to improve recognition of the condition amongst healthcare professionals**
 - **to optimise management of this condition in the Irish adult female population on an ongoing basis.**
-

Works Cited

- Weyers, W. (2013). Hypertrophic lichen sclerosus with dyskeratosis and parakeratosis--a common presentation of vulvar lichen sclerosus not associated with a significant risk of malignancy. *The American Journal of dermatopathology*, 35(7), 713-721.
- Bizjak Ogrinc, U., Senčar, S., Luzar, B., & Lukanović, A. (2019). Efficacy of Non-ablative Laser Therapy for Lichen Sclerosus: A Randomized Controlled Trial. *Journal of obstetrics and gynaecology Canada : JOGC = Journal d'obstetrique et gynecologie du Canada : JOGC*, 41(12), 1717-1725.
- Borghi, A., & Corazza, M. (2021). Novel Therapeutic Approaches and Targets for Treatment of Vulvar Lichen Sclerosus. *Current pharmaceutical biotechnology*, 22(1), 99-114.
- Borghi, A., Corazza, M., Minghetti, S., Toni, G., & Virgili, A. (2015). Continuous vs. tapering application of the potent topical corticosteroid mometasone furoate in the treatment of vulvar lichen sclerosus: results of a randomized trial. *The British journal of dermatology*, 173(6), 1381 - 1386.
- Bracco, G. L., Carli, P., & Sonni, L. (1993). Clinical and histologic effects of topical treatments of vulval lichen sclerosus. A critical evaluation. *Journal of Reproductive Medicine*, 38(1), 37-40.
- Bracco, G. L., Carli, P., Sonni, L., Maestrini, G., De Marco, A., Taddei, G. L., & Cattaneo, A. (1993). Clinical and histologic effects of topical treatments of vulval lichen sclerosus. A critical evaluation. *The Journal of reproductive medicine*, 38(1), 37-40.
- Bradford, J., & Fischer, G. (2010). Long-term management of vulval lichen sclerosus in adult women. *The Australian & New Zealand journal of obstetrics & gynaecology*, 50(2), 148-152.
- Burkett, L. S., Siddique, M., Zeymo, A., Brunn, E. A., Gutman, R. E., Park, A. J., & Iglesi, C. B. (2021). Clobetasol Compared With Fractionated Carbon Dioxide Laser for Lichen Sclerosus: A Randomized Controlled Trial. *Obstetrics and gynecology*, 137(6), 968-978.
- Casabona, F., Priano, V., & Vallerino, V. (2010). New surgical approach to lichen sclerosus of the vulva: the role of adiposederived mesenchymal cells and platelet-rich plasma in tissue regeneration. *Plastic & Reconstructive Surgery*, 126, 210-211.
- Casabona, F., Robello, G., & Cogliandro, A. (2008). Nuova terapia degli esiti di lichen sclerosus della vulva con L'impiego de cellule multipotenti di derivazione adipose e plasma ricco di piastrine: case report. *Riv Ital Chir Plast*, 40, 67-70.
- Cattaneo, A., Carli, P., De Marco, A., Sonni, L., Bracco, G., De Magnis, A., & Taddei, G. L. (1996). Testosterone maintenance therapy. Effects on vulvar lichen sclerosus treated with clobetasol propionate. *The Journal of reproductive medicine*, 41(2), 99-102.
- Cattaneo, A., Carli, P., De Marco, A., Sonni, L., Bracco, G., & De Magnis, A. (1996). Testosterone maintenance therapy. Effects on vulvar lichen sclerosus treated with clobetasol propionate. *Journal of Reproductive Medicine*, 41, 99-102.

- Cattaneo, A., Carli, P., De Marco, A., Sonni, L., Bracco, G., De Magnis, A., & Taddei, G. L. (1996). Testosterone maintenance therapy. Effects on vulvar lichen sclerosus treated with clobetasol propionate. *The Journal of reproductive medicine*, 41(2), 99-102.
- Cattaneo, A., De Marco, A., Sonni, L., Bracco, G. L., Carli, P., & Taddei, G. L. (1992). Clobetasol vs. testosterone in the treatment of lichen sclerosus of the vulvar region [Clobetasolo vs. testosterone nel trattamento del lichen scleroso della regione vulvare]. *Minerva Ginecologica*, 44, 567-71.
- Chamli, A., & Souissi, A. (2023, Jan). *Lichen Sclerosus*. [Updated 2023 Jul 31]. Retrieved Nov 20, 2023, from National Library of Medicine; StatPearls: <https://www.ncbi.nlm.nih.gov/books/NBK538246/>
- Chi, C. C., Kirtschig, G., Baldo, M., Brackenbury, F., Lewis, F., & Wojnarowska, F. (2011). Topical interventions for genital lichen sclerosus. *The Cochrane database of systematic reviews*(12).
- Cooper, S. M., Gao, X. H., Powell, J. J., & Wojnarowska, F. (2004). Does treatment of vulvar lichen sclerosus influence its prognosis? *Archives of dermatology*, 140(6), 702-706.
- Corazza, M., Borghi, A., Minghetti, S., Toni, G., & Virgili, A. (2016). Clobetasol propionate vs. mometasone furoate in 1-year proactive maintenance therapy of vulvar lichen sclerosus: results from a comparative trial. *Journal of the European Academy of Dermatology and Venereology : JEADV*, 30(6), 956-961.
- Corazza, M., Virgili, A., Toni, G., & Borghi, A. (2018). Mometasone furoate in the treatment of vulvar lichen sclerosus: could its formulation influence efficacy, tolerability and adherence to treatment? *The Journal of dermatological treatment*, 29(3), 305-309.
- Day, T., Selim, M. A., Allbritton, J. I., Scurry, J., & ISSVD Difficult Pathologic Diagnoses Committee. (2023). Nonsclerotic Lichen Sclerosus: Definition of a Concept and Pathologic Description. *Journal of lower genital tract disease*, 27(4), 358-364.
- De Luca, D. A., Papara, C., Vorobyev, A., Staiger, H., Bieber, K., Thaçi, D., & Ludwig, R. J. (2023). Lichen sclerosus: The 2023 update. *Frontiers in medicine*. 10, 1106318.
- Eshtiaghi, P., & Sadownik, L. A. (2019, Jan). Fact or Fiction? Adipose-Derived Stem Cells and Platelet-Rich Plasma for the Treatment of Vulvar Lichen Sclerosus. *Journal of Lower Genital Tract Disease*., 23(1), 65-70.
- Fischer, G. O. (1996). The commonest causes of symptomatic vulvar disease: a dermatologist's perspective. *The Australasian journal of dermatology*, 37(1), 12-18.
- Fischer, G., & Bradford, J. (2007). Topical immunosuppressants, genital lichen sclerosus and the risk of squamous cell carcinoma: a case report. *The Journal of reproductive medicine*, 52(4), 329-331.
- Fistarol, S. K., & Itin, P. H. (2013, Feb). Diagnosis and treatment of lichen sclerosus: an update. *Am J Clin Dermatol.*, 14(1), 27-47.
- Funaro, D. (2004). Lichen sclerosus: a review and practical approach. *Dermatologic therapy*, 17(1), 28-37.

- Funaro, D., Lovett, A., Leroux, N., & Powell, J. (2014). A double-blind, randomized prospective study evaluating topical clobetasol propionate 0.05% versus topical tacrolimus 0.1% in patients with vulvar lichen sclerosus. *Journal of the American Academy of Dermatology*, 71(1), 84-91.
- Günthert, A. R., Limacher, A., Beltraminelli, H., Krause, E., Mueller, M. D., Trelle, S., . . . Jüni, P. (2022). Efficacy of topical progesterone versus topical clobetasol propionate in patients with vulvar Lichen sclerosus - A double-blind randomized phase II pilot study. *European journal of obstetrics, gynecology, and reproductive biology*, 272, 88-95.
- Gil-Villalba, A., Ayen-Rodriguez, A., Naranjo-Diaz, M. J., & Ruiz-Villaverde, R. (2023). Laser Therapy for Vulvar Lichen Sclerosus, a Systematic Review. *Life (Basel, Switzerland)*, 13(11), 2146.
- Goldstein, A. T., Creasey, A., Pfau, R., Phillips, D., & Burrows, L. J. (2011). A double-blind, randomized controlled trial of clobetasol versus pimecrolimus in patients with vulvar lichen sclerosus. *Journal of the American Academy of Dermatology*, 64(6), e99-e104.
- Haefner, H. K., Aldrich, N. Z., Dalton, V. K., Gagné, H. M., Marcus, S. B., Patel, D. A., & Berger, M. B. (2014, Sep). The impact of vulvar lichen sclerosus on sexual dysfunction. *Journal of Women's Health (Larchmt)*, 23(9), 765-70.
- Hagedorn, M., Golüke, T., & Mall, G. (2003). Lichen sclerosus und Vulvakarzinom [Lichen sclerosus and squamous cell carcinoma of the vulva]. *Journal der Deutschen Dermatologischen Gesellschaft = Journal of the German Society of Dermatology: JDDG*, 1(11), 864-868.
- Halonen, P., Jakobsson, M., Heikinheimo, O., Riska, A., Gissler, M., & Pukkala, E. (2017). Lichen sclerosus and risk of cancer. *International journal of cancer*, 140(9), 1998-2002.
- Hengge, U. R., Krause, W., Hofmann, H., Stadler, R., Gross, G., Meurer, M., . . . Gollnick, H. (2006). Multicentre, phase II trial on the safety and efficacy of topical tacrolimus ointment for the treatment of lichen sclerosus.,. *The British journal of dermatology*, 155(5), 1021-1028.
- Higgins, C. A., & Cruickshank, M. E. (2012). A population-based case-control study of aetiological factors associated with vulval lichen sclerosus. *Journal of obstetrics and gynaecology : the journal of the Institute of Obstetrics and Gynaecology*, 32(3), 271-275.
- Krause, E., Neumann, S., Maier, M., Imboden, S., Knabben, L., Mueller, M. D., & Kuhn, A. (2023). LASER treatment in gynaecology -A randomized controlled trial in women with symptomatic lichen sclerosus. *European journal of obstetrics, gynecology, and reproductive biology*, 287, 171-175.
- Kreuter, A., Kryvosheyeva, Y., Terras, S., Moritz, R., Möllenhoff, K., Altmeyer, P., . . . Gambichler, T. (2013). Association of autoimmune diseases with lichen sclerosus in 532 male and female patients. *Acta dermato-venereologica*, 93(2), 238-241.
- Lee, A., & Fischer, G. (2018). Diagnosis and Treatment of Vulvar Lichen Sclerosus: An Update for Dermatologists. *American journal of clinical dermatology*, 19(5), 695-707.

- Lee, A., Bradford, J., & Fischer, G. (2015). Long-term Management of Adult Vulvar Lichen Sclerosus: A Prospective Cohort Study of 507 Women. *JAMA dermatology*, 151(10), 1061-1067.
- Leone, M., Gerbaldo, D., Caldana, A., Leone, M. M., & Capitanio, G. L. (1993). Progesterone topically administered influences epidermal growth factor immunoreactivity in vulvar tissue from patients with lichen sclerosus. *Cervix and the Lower Female Genital Tract*, 11, 25-27.
- Lewis, F. M. (2015). Treatment regimens in vulval lichen sclerosus. *The British journal of dermatology*, 173(6), 1355.
- Lewis, F. M., Tatnall, F. M., Velangi, S. S., Bunker, C. B., Kumar, A., Brackenbury, F., . . . Exton, L. S. (2018). British Association of Dermatologists guidelines for the management of lichen sclerosus. *The British journal of dermatology*, 178(4), 839-853.
- Luesley,, D. M., & Downey, G. P. (2006). Topical tacrolimus in the management of lichen sclerosus. *BJOG: an international journal of obstetrics and gynaecology*, 113(7), 832-834.
- McCarthy, S., MacEoin, N., O'Driscoll, M., O'Connor, R., Heffron, C. C., & Murphy, M. (2019). Should We Always Biopsy in Clinically Evident Lichen Sclerosus? *Journal of lower genital tract disease*, 23(2), 182-183.
- Mitchell, L., Goldstein, A. T., Heller, D., Mautz, T., Thorne, C., Joyce Kong, S. Y., . . . Krapf, J. M. (2021). Fractionated Carbon Dioxide Laser for the Treatment of Vulvar Lichen Sclerosus: A Randomized Controlled Trial. *Obstetrics and gynecology*, 137(6), 979-987.
- Murina, F., Rehman, S., Di Francesco, S., Mantegazza, V., Felice, R., & Bianco, V. (2015). Vulvar lichen sclerosus: a comparison of the short-term topical application of clobetasol dipropionate 0.05% versus mometasone furoate 0.1%. *Journal of lower genital tract disease*, 19(2), 149-151.
- Nic Dhonncha, E., & Murphy, M. (2022). Attitudes and advice-giving behaviours of pharmacists in relation to topical corticosteroid use for patients with lichen sclerosus. *Clinical and experimental dermatology*, 47(1), 190-192.
- Nic Dhonncha, E., O'Connor, C., O'Connell, G., Quinlan, C., Roche, L., & Murphy, M. (2021). Adherence to treatment with prescribed topical corticosteroid therapy and potential barriers to adherence among women with vulvar lichen sclerosus: a prospective cross-sectional study. *Clinical and experimental dermatology*, 46(4), 734-735.
- Oskay, T., Sezer, H. K., Genç, C., & Kutluay, L. (2007). Pimecrolimus 1% cream in the treatment of vulvar lichen sclerosus in postmenopausal women. *International journal of dermatology*, 46(5), 527-532.
- Paganelli, A., Contu, L., Condorelli, A., Ficarelli, E., Motolese, A., Paganelli, R., & Motolese, A. (2023). Platelet-Rich Plasma (PRP) and Adipose-Derived Stem Cell (ADSC) Therapy in the Treatment of Genital Lichen Sclerosus: A Comprehensive Review. *International Journal of Molecular Sciences*, 24(22), 16107.
- Paslin, D. (1991). Treatment of lichen sclerosus with topical dihydrotestosterone. *Obstetrics & Gynecology*, 78, 1046-9.

- Paslin, D. (1996). Androgens in the topical treatment of lichen sclerosis. *International Journal of Dermatology*, 35, 298-301.
- Pérez-López, F. R., & Vieira-Baptista, P. (2017). Lichen sclerosis in women: a review. *Climacteric : the journal of the International Menopause Society*, 20(4), 339-347.
- Pergialiotis, V., Bellos, I., Biliou, E. C., Varnava, P., Mitsopoulou, D., Doumouchtsis, S. K., & CHORUS, i.-c. (2020). An arm-based network meta-analysis on treatments for vulvar lichen sclerosis and a call for development of core outcome sets. *American journal of obstetrics and gynecology*, 222(6), 542–550.e6.
- Pope, R., Lee, M. H., Myers, A., Song, J., Abou Ghayda, R., Kim, J. Y., . . . Jacob, L. (2022). Lichen Sclerosis and Sexual Dysfunction: A Systematic Review and Meta-Analysis. *The Journal of Sexual Medicine*, 19(11), 1616-1624.
- Sideri, M., Origoni, M., Spinaci, L., & Ferrari, A. (1994). Topical testosterone in the treatment of vulvar lichen sclerosis. *International Journal of Gynaecology & Obstetrics*, 46, 53-6.
- Simonart, T., Lahaye, M., & Simonart, J. M. (2008). Vulvar lichen sclerosis: effect of maintenance treatment with a moisturizer on the course of the disease. *Menopause (New York, N.Y.)*, 15(1), 74-77.
- Singh, N., Mishra, N., & Ghatage, P. (2021). Treatment Options in Vulvar Lichen Sclerosis: A Scoping Review. . *Cureus*, 13(2), e13527.
- Sotiriou, E., Apalla, Z., Patsatsi, A., & Panagiotidou, D. (2009). Topical tacrolimus for recalcitrant vulvar lichen sclerosis. *European journal of dermatology*, 19(5), 515-516.
- Tasker, F., Kirby, L., Grindlay, D. J., Lewis, F., & Simpson, R. C. (2021). Laser therapy for genital lichen sclerosis: A systematic review of the current evidence base. *Skin health and disease*, 1(3), e52.
- Tasker, G. L., & Wojnarowska, F. (2003). Lichen sclerosis. *Clinical and experimental dermatology*, 28(2), 128-133.
- Van de Nieuwenhof, H. P., Meeuwis, K. A., Nieboer, T. E., Vergeer, M. C., Massuger, L. F., & De Hullu, J. A. (2010). he effect of vulvar lichen sclerosis on quality of life and sexual functioning. *Journal of psychosomatic obstetrics and gynaecology*, 31(4), 279-284.
- Villalpando, B. K., Wyles, S. P., Schaefer, L. A., Bodiford, K. J., & Bruce, A. J. (2021). Platelet-rich plasma for the treatment of lichen sclerosis. *Plastic and aesthetic research*, 8(63).
- Virgili, A., Borghi, A., Minghetti, S., & Corazza, M. (2014). Mometasone fuoroate 0.1% ointment in the treatment of vulvar lichen sclerosis: a study of efficacy and safety on a large cohort of patients. *Journal of the European Academy of Dermatology and Venereology : JEADV*, 28(7), 943-948.
- Virgili, A., Borghi, A., Toni, G., Minghetti, S., & Corazza, M. (2014). First randomized trial on clobetasol propionate and mometasone fuoroate in the treatment of vulvar lichen sclerosis: results of efficacy and tolerability. *The British journal of dermatology*, 171(2), 388-396.

- Virgili, A., Corazza, M., Minghetti, S., & Borghi, A. (2015). Growing evidence for topical mometasone fuoroate in the treatment of Vulvar Lichen Sclerosus. *Maturitas*, 80(1), 113-115.
- Virgili, A., Lauriola, M. M., Mantovani, L., & Corazza, M. (2007). Vulvar lichen sclerosus: 11 women treated with tacrolimus 0.1% ointment. *Acta dermato-venereologica*, 87(1), 69-72.
- Virgili, A., Minghetti, S., Borghi, A., & Corazza, M. (2013). Proactive maintenance therapy with a topical corticosteroid for vulvar lichen sclerosus: preliminary results of a randomized study. *The British journal of dermatology*, 168(6), 1316-1324.
- Vittrup, G., Westmark, S., Riis, J., Mørup, L., Heilesen, T., Jensen, D., & Melgaard, D. (2022, Jul 1). The Impact of Psychosexual Counseling in Women With Lichen Sclerosus: A Randomized Controlled Trial. *J Low Genit Tract Dis.*, 26(3), 258-264.
- Weyers, W. (2015). Hypertrophic lichen sclerosus sine sclerosis: clues to histopathologic diagnosis when presenting as psoriasiform lichenoid dermatitis. *Journal of cutaneous pathology*, 42(2), 118-129.
- Yıldız, Ş., Cengiz, H., Kaya, C., Alay, İ., Öztürk, E., Tunca, A. F., . . . Yaşar, L. (2022). Evaluation of genital self-image and sexual dysfunction in women with vulvar lichen planus or lichen sclerosus. *Journal of Psychosomatic Obstetrics and Gynaecology*, 43(2), 99-106.
- Yeon, J., Oakley, A., Olsson, A., Drummond, C., Veysey, E., Marshman, G., . . . Fischer, G. (2021). Vulval lichen sclerosus: An Australasian management consensus. *The Australasian journal of dermatology*, 62(3), 292-299.
- Yesudian, P. D. (2009). The role of calcineurin inhibitors in the management of lichen sclerosus. *American journal of clinical dermatology*, 10(5), 313-318.
-

APPENDIX: Adult Vulval Lichen Sclerosus Diagnosis and Treatment Summary

When to suspect LS; symptoms

- Itch
- Soreness/ burning pain (consequence of erosion or fissures)
- Dysuria
- Superficial dyspareunia
- Sensation of splitting/tearing
- May be (rarely) asymptomatic

Cases of 'recurrent candidiasis' with negative swabs

When to suspect LS; signs

See diagram

Treatment Initial Rx

The mainstay of treatment is super potent topical corticosteroids

Each regime should be tailored to the severity of patient's disease

However, dermivate ointment applied generously daily for 3/12 is a reasonable starting regime for primary and secondary care

Reassurance should be provided regarding the safety of potent TCS when used appropriately and in the correct location

Thinning of the skin with TCS is minimal compared to risk of loss of architecture with untreated disease

Demonstration of site to be treated with a mirror or (patient's own) digital device may be helpful

At review...

Review after three months of treatment is required

If the patient is not improving, consider referral to a dermatologist/gynaecologist with expertise in the management of vulval dermatoses

If symptomatically improving, continue treatment until there is no clinical sign of active disease

Once symptomatically and clinically in remission – decrease frequency of application rather than volume used – e.g. initially reduce to application of TCS on alternate days

Treatment success..

Treatment success can be determined by improvement in; symptoms (itch, dyspareunia etc.)

signs (hyperkeratosis, ecchymosis, fissuring, erosions)

Note; anatomical loss and colour change will remain despite adequate treatment

(Photo of well controlled LS with architectural change)

Psychological impact

LS has the potential to be associated with significant impacts upon quality of life and sexual functioning

Open discussion of the impact on the woman's sexual health should be carried out at the time of presentation

Referral if required to counselling/psychological support

physiotherapy for dyspareunia ('anti-Kegele' exercises)

Hypertrophic LS

Subtype of LS where dermal sclerosis is absent histologically

Involved tissues may appear clinically atypical, with a thickened whitish appearance

Refer to secondary care in light of the potential diagnostic challenge and unclear prognosis

Biopsy

LS is primarily a clinical diagnosis; confirmatory biopsy is not required if the clinical findings are typical

Biopsy may be recommended if there is;

- diagnostic uncertainty
- atypical clinical findings
- a lack of expected response to adequate treatment

Any suspicion for neoplastic change or VIN

Maintenance

A typical maintenance regime would include; clobetasol 0.05% once/twice weekly to maintain control of disease activity

Maintenance treatment should aim to;

- Maintain normal/near normal colour/texture of vulval skin
- Control symptoms
- Prevent future scarring
- Minimise side effects
- Reduce carcinoma risk

Patients should be empowered to undertake regular self-examination and educated regarding the red flag symptoms for development of neoplastic change that should prompt expedited clinical review

There is no evidence for...

- Topical sex hormones
- Topical calcineurin inhibitors
- Stem Cell therapies and Platelet rich plasma
- LASER treatment (ablative or non-ablative)

There is limited evidence for...

- Emollients/soap substitutes which may aid symptomatic comfort

Follow up

Until clinically stable

Evidence supports maintenance treatment with dermivate once weekly in quiescent LS;

Patients with clinically inactive LS need a yearly vulval exam in view of (small) SCC risk

The skill of self examination should be encouraged

Vulval SCC in LS; estimated risk is up to 5%